



Egyptian Journal of Animal Health

P-ISSN: 2735-4938 On Line-ISSN: 2735-4946
Journal homepage: <https://ejah.journals.ekb.eg/>

Amyloodinium ocellatum (Dinoflagellate protozoa) Infestation in *Dicentrarchus labrax* (Sea bass) and trials of treatment

Dawlat A. Hassanin * ,Eman M. Abouelhassan ** ,Walaa El-Shaer ***

*Central Laboratory of Fisheries Resources, Al-Raswa branch, Port Saied, Egypt.

** Department of Parasitology, Faculty of Veterinary Medicine, Suez Canal University, Egypt.

*** Agriculture Research Center (ACR), Animal Health Research Institute, Ismailia branch, Unit of Fish Diseases, Egypt.

Received in 20/8/2023
Received in revised from
27/9/2023
Accepted in 14/10/2023
.....

Keywords:

Amyloodinium ocellatum
Dicentrarchus labrax
Electron Microscope
Copper sulfate
Hydrogen peroxide.

ABSTRACT

Amyloodiniosis (marine velvet, velvet disease) is one of the main problems in aquaculture, in this study, A total 300 of European *Dicentrarchus labrax* fingerlings, were collected randomly from a fishing farm at Port Said governorate, Egypt, in the summer of 2022. Samples were taken for the parasitological examination (light and electron microscopical examination) which revealed the presence of *Amyloodinium ocellatum*, for the experimental design. The total Prevalence of the 300 examined *Dicentrarchus labrax* fish, was 195 (65.00%), a total of 240 *D. labrax* fingerlings were divided into four equal groups of 60 each and distributed equally in fiberglass tanks, and both Copper sulfate and hydrogen peroxide were used in the treatments for 14 days, giving good recovery with decreasing the mortalities rates. The identification is confirmed by scanning electron microscope.

INTRODUCTION

Amyloodinium ocellatum, the causative agent of amyloodiniosis (marine velvet, or velvet disease), is one of the main problems in aquaculture, which was previously reported in the aquaculture of the Mediterranean region (Soares et al. 2012). These parasites can attach to the gills, the primary site of infestation for Amyloodiniosis. infestation may also involve the skin, fins, and eyes. It can penetrate deeply into the epithelium using a rhizoid root-like structure, leading to severe damage to tissue at

the site of attachment. In addition, their rapid reproduction, causes high morbidity and mortalities, especially in cultured fish with high density. Therefore, *A. ocellatum* can cause serious economic losses in aquaria and the mariculture systems (Byadgi et al. 2020). Concerning their life cycle, *Amyloodinium ocellatum* is an extracellular obligatory parasite that involves three developmental stages, one of which is the free-living phase; *A. ocellatum* requires its host fish to survive and complete its life cycle (Ranjbar and Khoramian, 2019). Sea

Corresponding author: Walaa El-Shaer , Agriculture Research Center (ACR), Animal Health Research Institute, Ismailia Branch, Unit of Fish Diseases, Egypt.

E-mail: dr_w2a@yahoo.com

DOI: 10.21608/ejah.2024.326630

bass is a marine fish of great economic importance particularly in Mediterranean aquaculture (Salama and Yousef, 2020). *Dicentrarchus labrax* seabass represents a major fisheries and aquaculture species in the Mediterranean, the European Atlantic coasts, and North Africa. Most fish living within its ecological range are susceptible to infestation with amyloodiniosis

Copper sulfate has been used extensively to treat infestations brought on by protozoa because it is one of the most effective chemicals against several parasitic infestations and diseases (Zhou et al. 2023). The cupric ion interferes in linking ionic regulatory proteins by obstructing their regulatory function (Hassan et al. 2017). Besides hydrogen peroxide plays an important role in cell protection against oxidative damage in unicellular eukaryotes which induces the expression of the detoxifying enzymes (Heo et al. 2020), which serves as a sensor and warning, enabling the cell to defend itself from oxidative stress. H₂O₂ is a significant Cellular Reactive Oxygen species that plays critical regulatory and signaling roles. It is highly damaging and reactive toward proteins, DNA, and lipids (Seixas et al. 2022).

The present study aimed to determine the pathogenesis and trials for the treatment of Amyloodiniosis in naturally infested Mediterranean aquaculture associated with morbidity and mortalities in seabass *Dicentrarchus labrax*

MATERIAL AND METHODS

Sample collection and clinical examination:

A total of 300 European *D. labrax* fingerlings were collected randomly from a fishing farm at Port Said governorate, Egypt, in the Summer of 2022. The fish samples were transported alive in oxygenated plastic bags with marine water and supplied with an aerator according to El-Deen et al. (2013), they were acclimatized in fiberglass aquaria for conduction of treatment trial of *A. ocellatum* partially filled with marine water. Clinical investigations and Post-Mortem (PM) examinations were performed according to Noga, (2010). The infestation rate of collected fish with Amyloodiniosis was 195

(65 %), we have used 180 divided into three groups in the experiment. The fourth group was taken from the rest collected fish as a control.

Parasitological examination:

Macroscopic examination.

Skin surfaces, fins, and gills were examined grossly for any abnormalities of parasites, and lesions.

Light microscopical examination

Direct wet mount techniques (skin scraping) and gill biopsy or gill clip (at which a gill filament is removed) are examined microscopically

Electron microscopical examination

Samples were preserved in glutaraldehyde, and then they were mounted on SEM stubs and were coated with gold using SI50A sputter coater and examined by scanning electron microscopy (JSMIT100 In Touch Scope™ Scanning Electron Microscope, JOEL, Damansara, Selangor, Malaysia) according to Abouelhasan, (2022).

Experimental design

A total of 240 from the collected 300 *D. labrax* fingerlings, 17 ± 3 g. weight, and (13 ± 1.50) cm length, 180 fish from 195 infected one divided into three equal groups of 60 (G1, G2, G3) and, 60 (G4) from the healthy one, distributed equally in fiberglass tanks size (1000L) Table 1.

Therapeutic Doses Efficacy against Amyloodiniosis:

Each treatment was performed in triplicates. Fish were equally distributed into the four groups of *D. labrax*, the first was the infested non-treated group (G1), the second infested group was immersed with copper sulfate (aqua clear: it is a mixture of copper sulfate, acetic acid, citric acid, and formic acid) at 0.25 ml/m³ (G2). The third infested was immersed with H₂O₂ 50% at 1.5 ml/m³ (G3) and the fourth one was apparently healthy non-treated group (G4). The experiment was inspected daily for 14 days, fish were fed on a well-balanced diet and changed 10 to 20% of water

daily. The clinical signs and mortality were recorded.

Ethics:

This study was conducted following legal ethical guidelines of the Medical Ethical Committee of the National Research Center, Dokki, Egypt. (Ethical approval no. ARC AHRI 2306).

RESULTS

Clinical and post-mortem findings

Naturally infested fish samples with various clinical symptoms like darkening of the skin color, off food, abnormal swimming behavior as a jerky movement, and moving upside down with severe respiratory distress, depression, anorexia, anoxia, gasping of mouth and sudden collapse, the gills were very pale with excess mucous. Although the protozoan cannot be seen with the naked eye. The total infestation rate was 65%

Parasitological findings

Microscopically, Smears were prepared from the skins, fins, and gills of the infested fish before the treatment, showing *Amyloodinium ocellatum* trophonts which are spherical, oval, and or elliptical in shape and attached to the gills or the skin surface (Fig. 1A).

The SEM, showed the *Amyloodinium* trophonts were round or spherical with different sizes from 40 to 60 μm (Fig. 1C). They were found in groups each group consisted of 3 to 6 trophonts or appeared separately attached firmly to the gill filaments, and the skin surface and between lamellae (Fig. 1D). The base of trophonts was narrow which is inserted in the tissues. This insertion of *Amyloodinium* trophonts led to changes in the gill and skin surface structures, for instance, the filaments appeared enlarged and swollen, with fusion of some lamellae (Fig. 1B)

Treatment trials

The effects of the treatment were evaluated by measuring both the infestation and mortality rates, besides the detection of the parasite num-

ber from the samples of each group, which showed a decrease of both infestation and mortality rates compared with the infected non-treated group, in the copper sulfate (aqua clear) treated group (G2), the recovery rate was 95%. Meanwhile, the hydrogen peroxide group (G3) was 71.66 % (Table 1 and Fig. 2&3). The treated fish regained its viability, appetite, and normal movement besides the disappearance of skin darkness, with normal gills appearance

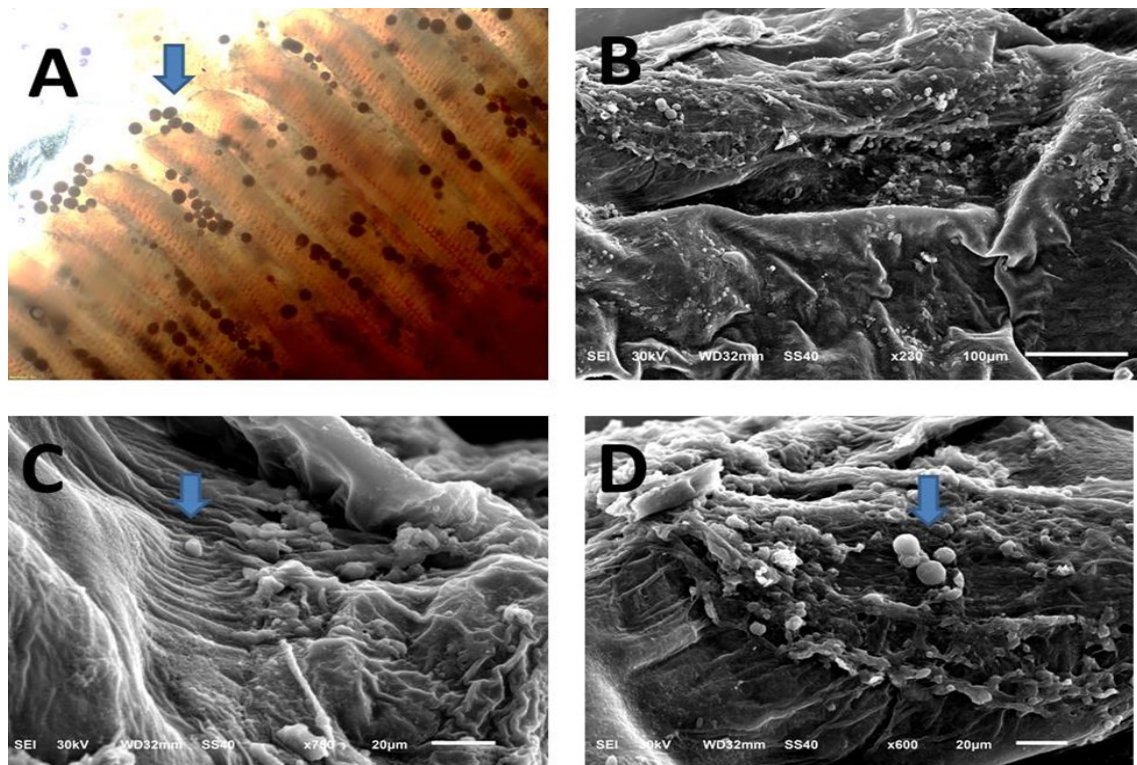


Figure 1. A freshly prepared smear from the gills of infected fish showing *Amyloodinium ocellatum* trophonts appear as clustered attached to the gills. (B, D): Scanning electron microscopy of *A. ocellatum* trophonts on the skin surface of the infected fish. (C): Scanning electron microscopy of *A. ocellatum* trophonts on the gills of the infected fish




Figure 2. Freshly prepared smears of the gills showing the low numbers of *A. ocellatum* trophonts during the treatment (A, B, C gills), (D, E on the skin surface)

Table 1. The effect of the treatment on the infected fish groups

groups	Dose	recovery rate		Infestation rate		Mortality	
		number	(%)	number	(%)	number	(%)
(G1)	-	-	-	60	100	13	21.66
(G2)	0.25 ml/m3	57	95	3	5	3	5
(G3)	1.5 ml/m3	43	71.66	17	28.33	9	15.00
(G4)	-	-	-	-	-	-	-

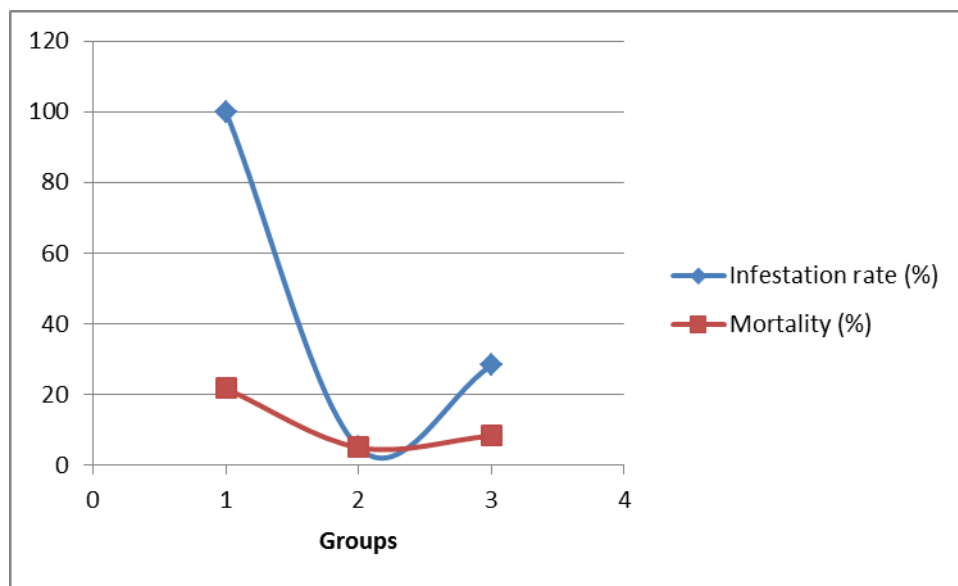


Figure 3: Infestation and mortality rates of the groups (G1, G2, G3) after the treatments.

DISCUSSION

Parasites have a direct life cycle mainly present intensively in farmed fish, especially in the presence of high biomass density (Soares et al. 2012), one of these important parasites is *Amyloodinium ocellatum* which is protozoa attached to the host's gills, skin, or fins (Ragab et al. 2022). In the present study, the clinical signs of the diseased fish were darkening skin color, off food, abnormal swimming behavior as a jerky movement, and respiratory distress nearly agreeing (Seoud et al. 2017, Osman et al. 2019, Ranjbar and Khoramian 2019 and Ragab et al. 2022). The total infestation rate was 65%, which is lower than (Bessat and Fadel, 2018), it was 84.86 from Wadi El-Natroun. In a while agree to (Seoud et al. 2017) it was 58.02% and (Osman et al. 2019)

67.8% from *Seabass Barramundi* and 58.4% from Hamour *Epinephelus polyphekadion*. On the other hand, the prevalence was higher than (Bessat and Fadel, 2018), it was 39.58% at El-Max station, Alexandria Governorate. This variation may be due to the difference in time of investigation, the place from which the fish were collected, the number, and of the age examined fish. Concerning the treatment, the use of chemicals should eliminate the pathogen at concentrations that do not harm the host, so the safe level of a chemical for a particular fish species must be established first before it can be used for treatment (Virgula et al. 2017). Most problems associated with parasites in aquaculture are mainly due to their ability to transmit without the need for an intermediate host, besides the outbreaks on farms are a re-

sult of both increased stress in the host and decreased water quality (Austin and Newaj-Fyzul, 2017). Copper sulfate is not a skin irritant, which is classified by the U.S. EP (United States Environmental Protection Agency) as very low in toxicity for dermal irritation (Chalk 2006). The toxicity of copper to fish and other aquatic life depends on its bioavailability, which is strongly dependent on pH, the presence of dissolved organic carbon (DOC), and water chemistry such as the presence of calcium ions (Christopher, 2022). The optimum pH of parasitic infestation ranged between (8 and 8.5) but the peak of infestation was recorded at pH 8.2 (Seoud et al. 2017). Despite fish kills were reported because of the copper sulfate addition of ration for algae control in ponds and lakes, it was cited that the death because of plant death and decomposition leading to oxygen depletion in addition to the dead organisms clogging the gills (Masser et al. 2013).

Hydrogen peroxide is a long-range, quick-acting signaling molecule that can diffuse through cellular membranes (Rhee et al. 2010). By modulating cytokines and growth factors, hydrogen peroxide can function as a signaling molecule to manage division, differentiation, and cell migration. Hydrogen peroxide is considered to be relatively safe for the environment, when added to water, breaks down into oxygen and water over time, so it is ideal for use in aquaculture against numerous external fish diseases. The gill microbial community is particularly exhibit to external environmental stressors due to direct exposure to the external environment, so drug treatments disrupt the gill microbial community, which may, in turn, increase the host's susceptibility to other opportunistic pathogens (Zhang et al. 2023). Exposure to potassium permanganate and H₂O₂ resulted in significant disturbances to the external microbiomes. So, we need to change 10 to 20% of the water daily. Our study used copper sulfate at 25mg./L. with naturally infested *D. labrax* fingerlings, 17 ± 3 g. recorded 95% recovered. Otherwise, the hydrogen peroxide group (G3) was 71.66 % with H₂O₂ 50% at 1.5 ml/m³.

The dose used of copper sulfate is directly

proportional to the weight of the fish and inversely proportional to the exposure period, i.e. (Osman et al. 2019) used 0.03 mg/L as a prolonged bath for the Red Sea cultured Asian Seabass broad stock (300-2500 g. fish body weight). While (Bessat and Fadel, 2018) treated marine-cultured European seabass *Dicentrarchus labrax* fry with copper sulfate applied at a concentration of 0.30 mg/L in a daily routine for 14 days, Ragab et al. (2022) used 1 g weighed European sea bass (*D. labrax*) was used as a prolonged bath at 0.2 mg/L for 7 days, after using florfenicol, hydrogen peroxide (H₂O₂), and a combination of treatments. The mortality rate was 21.66 %, 5%, and 15% in groups G1, G2, and G3 respectively as a result of the decrease in immunity due to the severity of the infestation which led to the destruction of gill filaments and respiratory dysfunction

CONCLUSION

The present investigation revealed that the treatment of choice for Amyloodiniosis was copper sulfate, which achieved 95% efficacy followed by hydrogen peroxide bath which was 71.8 %, prolonged treatment for 14 days respectively was recommended to give good results with resistant stages. The copper sulfate is affordable, effective, and accessible at almost every fish store, it will probably continue to be a good therapy for a while, it has been documented to be effective in controlling parasite infestations

REFERENCES

- Abouelhasan EM. 2022. Light and Scanning Electron Microscopic Studies on *Caligus spp.* In Mugilid fish. Egyptian Veterinary Medical Society of Parasitology Journal (EVMSPJ) (18): 35-44.
- Austin B, Newaj-Fyzul A. 2017. Diagnosis and control of diseases of fish and shellfish: Wiley Online Library.
- Bessat M, Fadel A. 2018. Amyloodiniosis in cultured *Dicentrarchus labrax*: parasitological and molecular diagnosis, and an improved treatment protocol. Diseases of aquatic organisms, (129): 41-51.
- Byadgi O, Marroni F, Dirks R, Massimo M, Volpatti D, Galeotti M, Beraldo P. 2020.

- Transcriptome Analysis of *Amyloodinium ocellatum* Tomonts Revealed Basic Information on the Major Potential Virulence Factors Genes, (11): 1252.
- Chalk I. 2006. US Environmental Protection Agency, Office of Prevention, Pesticides and Toxic Substances, Office of Pesticide Programs. TUV Ce Certified Commercial Outdoor Kids Fitness Playground Gym Equipment (accessed Jan 2008), updated May.
- Christopher A, Mebane. 2022. Bioavailability and toxicity models of copper and zinc to freshwater life: the state of the science and alternatives for water quality criteria U.S. Geological Survey, Idaho Water Science Center, Boise Idaho, USA.
- El-Deen AN, Mahmoud A, Hassan A. 2013. Field studies of caligus parasitic infections among cultured seabass (*Dicentrarchus labrax*) and mullet (*Mugil cephalus*) in marine fish farms with emphasis on treatment trials. *Global Veterinaria* (11): 511-520.
- Hasan K, Cheng Y, Kanwar MK, Chu X, Ahammed GJ, Qi Zhen-Yu. 2017. Responses of Plant Proteins to heavy metal stress a review. *Frontiers in Plant Science*, Volume 8 Article 1492
- Heo S, Kim S, Kang D. 2020. The Role of Hydrogen Peroxide and Peroxiredoxins throughout the Cell Cycle. *Antioxidants* (9): 280
- Masser M, Murphy T, Shelton J. 2013. Aquatic Weed Management: Herbicides. Southern Regional Aquaculture Center, Publication No. 361.
- Noga EJ. 2010. Fish disease: diagnosis and treatment: John Wiley & Sons.
- Osman HAM, El-Battawy KA, Brayka AZ Abu, Noor El-Deen AI, Zaki MS, Rabie NS, Kenawy AM. 2019. Field Studies on Amyloodiniosis in Red Sea Cultured Asian Seabass (*Lates calcarifer*) and Hamour (*Epinephelus polyphekadion*). *Pakistan Journal of Biological Sciences: PJBS* (22): 349-355.
- Ragab RH, Elgendy MY, Sabry NM, Sharaf MS, Attia MM, Korany RM, Abdelsalam M, Eltahan AS, Eldessouki EA, El-Demerdash GO. 2022. Mass kills in hatchery-reared European seabass (*Dicentrarchus labrax*) triggered by concomitant infections of *Amyloodinium ocellatum* and *Vibrio alginolyticus*. *International Journal of Veterinary Science and Medicine* (10): 33-45.
- Ranjbar HR, Khoramian S. 2019. First Report of *Amyloodinium ocellatum* (E. Brown) E. Brown & Hovasse, 1946 (Dinoflagellate, *Blastodiniiales*, *Oodiniaceae*) from Sobaity Seabream, *Sparidentex hasta* (Valenciennes, 1830) Cultured in Persian Gulf of Iran. *Aquaculture Studies* (19): 77-80.
- Rhee SG, Chang TS, Jeong W, Kang D. 2010. Methods for detection and measurement of hydrogen peroxide inside and outside of cells. *Molecules and Cells* (29): 539-549.
- Salama SSA, Yousef NSI. 2020. The impact of co-infection of sea lice and its concurrent some bacterial diseases with field treatment trials in some marine cultured fishes. *Egyptian Journal of Aquatic Biology & Fisheries*. 24 (7): 363 – 381
- Seixas AF, Quendera AP, Sousa JP, Silva AFQ, Arraiano CM, Andrade JM. 2022. Bacterial Response to Oxidative Stress and RNA Oxidation. *Frontiers in Genetics*, vol. 12 article 821535.
- Seoud SSM, Zaki VH, Ahmed GE, Abd El-Khalek NK. 2017. Studies on *Amyloodinium* infestation in European seabass (*Dicentrarchus labrax*.) fishes with special reference for treatment. *International Journal of Marine Science* 7.
- Soares F, Quental-Ferreira H, Moreira M, Cunha E, Ribeiro L, Pousão-Ferreira P. 2012. First report of *Amyloodinium ocellatum* in farmed meagre (*Argyrosomus regius*). *Bulletin of the European Association of Fish Pathologists*. (32): 30-33.
- Virgula JC, Cruz-Lacierda ER, Estante EG, Corre Jr VL. 2017. Copper sulfate as treatment for the ectoparasite. *Amyloodinium ocellatum* (Dinoflagellida) on milkfish fry. *AAFL Bioflux*, Vol. 10, Issue 2.
- Zhou S, Yang Q, Song Y, Cheng B, Ai X. 2023. Effect of Copper Sulphate Exposure on the Oxidative Stress, Gill Transcriptome and External Microbiota of Yellow Catfish, *Pelteobagrus fulvidraco*. *Antioxidants* (12):1288.
- Zhang R, Wu GT, Zhu JY, Wang XW, Liu LL, Li HJ, Zhu H. 2023. Povidone iodine exposure alters the immune response and microbiota of the gill and skin in koi carp, *Cyprinus carpio*. *Aquaculture*;(563):738926